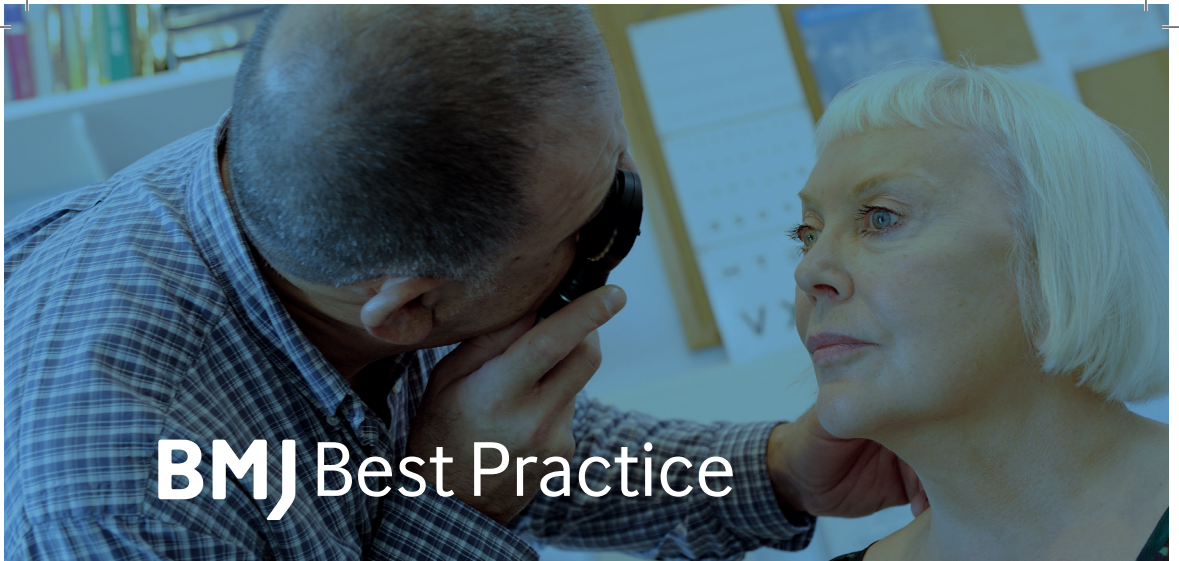



BMJ Best Practice

A 64-year-old woman presents to the emergency department with severe pain around her right eye.

She has had the pain for 4 hours. She also has blurred vision in that eye and feels nauseated. Examination shows a red right eye with an oedematous cornea and a wide pupil that is unresponsive to light. Intra-ocular pressure is 60 mmHg in the right eye. The anterior chamber angle is closed in both eyes.



How would you diagnose this patient?

What differentials should you consider?

What is the most effective treatment?

Find the answer to this and other important clinical questions on BMJ Best Practice.

Available to all NHSScotland staff and partners, BMJ Best Practice provides step by step guidance on diagnosis, prognosis, treatment and prevention.

knowledge.scot.nhs.uk












BMJ Best Practice

Available to all NHSScotland staff and partners

BMJ Best Practice unique differentials tables guide you through making a diagnosis, and our treatment algorithms, with links to drug databases and Cochrane Clinical Answers, help you to determine the best course of care for your patients.

Other Ophthalmology topics include:

-  Amblyopia
-  Eye trauma
-  Retinoblastoma
-  Corneal abrasions
-  Open-angle glaucoma
-  Stye and chalazion
-  Diabetic retinopathy
-  Orbital fractures
-  Trachoma

How to Access

1. Visit The Knowledge Network - knowledge.scot.nhs.uk to access the BMJ Best Practice website
2. If necessary, sign in with your NHSScotland OpenAthens username via the 'Log In' link
3. You can register for a BMJ Best Practice personal account for access to added features like the mobile app and CME/CPD activity tracking. Click 'Create an account' or 'Log in' if you are already registered.
4. You now have a personal BMJ Best Practice personal account.

knowledge.scot.nhs.uk